



Comparative Efficacy of Zinc Oxide Nanoparticles and Citric Acid on Surgically Incised Wound in Rabbit

Rizwan Abdul Aleem¹, Asad Khan^{2,3*}, Shafqat Naeem¹, Muhammad Tahir Aleem⁴, Iftikhar Ali Khan⁵, Abdul Qadeer⁶, Shakeel Ahmed³, Sadaf Aslam^{3,7} and Ashar Mehfooz¹

¹Department of Clinical Medicine and Surgery, University of Agriculture Faisalabad.

²Faculty of Veterinary and Animal Sciences, Gomal University, D.I. Khan

³Department of Anatomy and Histology, University of Veterinary and Animal Sciences, Lahore.

⁴MOE Joint International Research Laboratory of Animal Health and Food Safety, College of Veterinary Medicine, Nanjing Agricultural University, Nanjing 210095, China

⁵Shenzhen Key Laboratory of Marine Microbiome Engineering, Institute for Advanced Study, Shenzhen University, Shenzhen, China

⁶Shanghai Veterinary Research Institute, Chinese Academy of Agricultural Sciences, Shanghai 200241, China

⁷Department of Veterinary Medicine, University of Veterinary and Animal Sciences, Lahore.

Rizwan Abdul Aleem and Asad Khan are co-first authors.

ABSTRACT

The purpose of this study was to compare the effects of zinc oxide (ZnO) nanoparticle ointment and Citric acid on the rate of wound healing, dermis thickness, and collagen content. For this purpose, five live rabbits were used. In each rabbit, three wounds were created by surgery. Wound A was treated with ZnO nanoparticles, wound B with citric acid ointment, and wound C was washed with normal saline. The wound healing effects were checked by using an arbitrary scoring system at different time intervals: the contraction rate of wounds, wound healing times, and tissue tensile strengths. The ZnO nanoparticles were found to be significantly effective in term of wounds healing and re-epithelization, and collagen content. Histopathological investigation revealed that treatment with ZnO nanoparticles produced better dermis thickness than balm of citrus extract and regular saline. In conclusion, the wound treated with topical application of ointment of ZnO nanoparticle in rabbits enhances wound healing enclosure in a significant way, and this was ascertained by histological study.

INTRODUCTION

A wound is a break in the mucus membrane or tissue surface of the skin caused by physical, chemical, or biological agents (Chhabra *et al.*, 2017). In everyday pathology, wounds continue to be a difficult clinical problem, causing both early and late complications posing

a significant risk of mortality and morbidity (Natarajan *et al.*, 2000). Injury that results in a wound is one that occurs quickly and includes tearing, puncturing, or cutting the skin (an open wound) or blunt force trauma (a contusion). For pets, companions, and working animals, wounds are a prevalent health issue in both developing and developed nations. Wound in developing countries, on the other hand can cause serious economic problems for dairy farmers due to insufficient hygiene measures. Secondary bacterial infection occurs in most of the cases (Sandhya *et al.*, 2021).

Healing wounds involves a well-defined biological process of regenerating tissue: It is divided into three distinct, yet overlapping phases that are characterized by inflammation, proliferation, and maturation (Ahmed *et al.*, 2019). Furthermore, the wound healing mechanism is characterized by complex interactions between various

* Corresponding author: asad.khan@gu.edu.pk
0030-9923/2023/0001-0001 \$ 9.00/0



Copyright 2023 by the authors. Licensee Zoological Society of Pakistan.

This article is an open access article distributed under the terms and conditions of the Creative Commons Attribution (CC BY) license (<https://creativecommons.org/licenses/by/4.0/>).

Article Information

Received 07 September 2022

Revised 05 December 2023

Accepted 12 December 2023

Available online 01 August 2024
(early access)

Authors' Contribution

AM, RAA, AK and SN conceived and designed the experiment. SN and MTA performed the experiments; AQ, AK, MTA and SA contributed reagents, materials and analysis tools. AK and AQ wrote a paper.

Key words

Zinc oxide nanoparticles, Citric acid, Wound healing, Collagen, Rabbits

cell types, extracellular matrix components, and cytokine mediators (Stojadinovic *et al.*, 2008). Even though the natural wound healing mechanism is activated when a wound is introduced, the wound should be dressed appropriately. To improve the healing process, the dressing should be able to intervene at the precise stage of wound healing or provide the right environment for the wound to heal (Ahmed *et al.*, 2019).

The most important immediate treatment for any animal with a wound is to stop the bleeding (Sandhya *et al.*, 2021). Treatment with antibiotics and anti-inflammatory agents is likely to relieve pain and aid healing (Norman *et al.*, 2016).

The nanoparticles of ZnO have key importance especially for wound healing process because of its high efficacy, penetration power and improved antimicrobial properties against clinically relevant microbial pathogens such as *S. aureus* (Ghasemi and Jalal, 2016), *P. aeruginosa* (Xie *et al.*, 2011), and *E. coli* (Souza *et al.*, 2019). Zinc oxide can be employed as a topical dose form for both hydrophilic and lipophilic drugs (Gupta *et al.*, 2014; Holmes *et al.*, 2016; Negut *et al.*, 2018). The most promising ZnO APIs are nanoparticles because they are tiny in size and have a big surface area that is ideal for immobilizing xymedone. Due to their capacity to produce reactive oxygen species, ZnO nanoparticles also possess wound healing, anti-inflammatory, and antibacterial characteristics (Sheferov *et al.*, 2022). In contrast, only 7–20 applications of citric acid are required to prepare the wound bed. It has also been demonstrated to be secure, non-toxic, dependable, and cost-effective (Malu *et al.*, 2016). Therefore, in the present study our main aim was to determine comparative efficacy of nano ZnO and citric in acid wound healing.

MATERIALS AND METHODS

Animals rearing and maintenance

A local market was used for obtaining the experimental animals and the Laboratory animals were maintained in Clinical Medicine's Laboratory animal facility for three weeks prior to their use in the experiment. The animals were kept in clean bedding, proper ventilation, and were allowed access to fresh water *ad libitum*. Fresh fodder was provided twice a day. Deworming was carried out a week before experiment by giving two doses of ivermectin @ 200 µg/kg subcutaneously.

Animals preparation and wound creation

A total of 5 rabbits of either sex with 2.5-3.0 kg body were used in this study. The animals were kept off-feed before surgical procedure. The trunk area of each rabbit was properly trimmed with the help of electric trimmer and

scrubbed with a general cleaning agent. The shaved area was properly disinfected with methylated spirit and tincture iodine. Animals were incised under general anesthesia at a dose rate of 15-30 mg/kg body weight (Ketamine hydrochloride, trade name Ketarol). Three surgical incision of (1cm X 1cm) were given in the shaved area. The incised wounds were marked A, B, and C with permanent marker to differentiate the treatments applied to them.

Treatment protocol

The wound A of each animal was treated with ZnO nanoparticle ointment (0.5% in paraffin), wound B with citric acid ointment (3% in petroleum jelly), and wound C with normal saline, and the control wounds that were not treated with ZnO nanoparticle ointment. The drugs application was started from day 1st, and healing was monitored on daily basis. Each and every animal was kept in separate cage and general health status (i.e., temperature, hearth, pulse, and breathing rate etc.) of animals were monitored at different time interval.

Assessment of wound healing

In order to determine the physical appearance of wounds, the ir closure and photographs of the wounded areas were taken repeatedly at different times using a digital camera. In wound healing assay, wound contraction rate, healing time and estimation of collagen content were checked for evaluation of wound healing.

Digital vernier caliper was used to measure the wound dimension in mm and to see the reduction in wounded area.

The healing process was evaluated on daily basis until scar tissue fell off.

For histopathology, samples were fixed in 10% formalin, and prepared for embedding in paraffin. Histological sections were cut and then stained with heamatoxyline and eosin. The stained sections were observed using light microscope. Each slide was examined under a magnifying lens at 200x in histometric methods. Using Nikon Opt iPhoto 2, photomicrographs were obtained from each slide. A computerized picture examination framework named as "Image J" was utilized to decide the measurement of dermis layers. Collagen content was estimated in regenerated wound tissue.

Statistical analysis

The statistical analysis was carried out using SPSS version 20. ANOVA were used to determine whether the results have significance variation and a P-value ≤ 0.05 was considered acceptable.

RESULTS

Figure 1 shows wound contraction rate in all the

wounds treated with saline, citric acid and ZnONP. By day 18, wounds treated with ZnO nanoparticles were healed to the point where contractions abated. On the other hand, wounds treated with citric acid ointment showed a subsiding contraction rate by day 24. Similarly, wounds treated with normal saline, which was also our control group, showed a decline in contraction rates by day 26. A wound treated with ZnO nanoparticles showed statistically significant ($p < 0.05$) fastest wound contraction time, compared with the wound treated with citric acid ointment and normal saline.

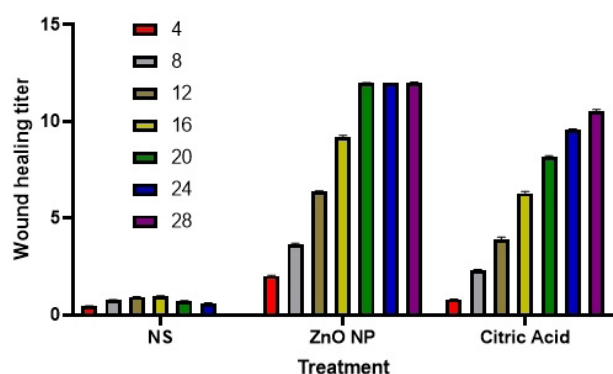


Fig. 1. Effect of citric acid, ZnONP on wound healing rate compared with that of normal saline.

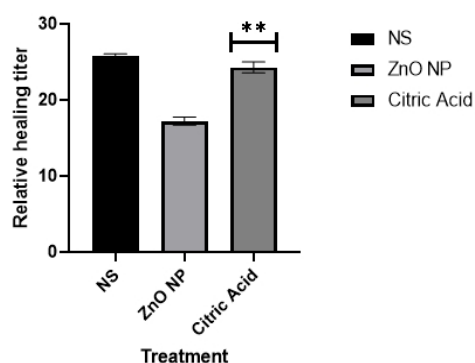


Fig. 2. The cumulative wound healing time after application of normal saline, ZnONP and citric acid.

With respect to wound mending time, the injuries treated with an application of ZnO nanoparticles balm showed the shortest recovery time, followed by citrus extract salve, and finally usual saline. Subsequently, ZnO nanoparticle balm had better benefits for healing in less time than the other two therapies (Fig. 2). Hence, it is concluded that healing time of NS and citric acid was considerably higher as compared to ZnO ($p > 0.05$).

Table I shows the measurement of epidermal,

dermal, and collagen thickness of the histopathological preparation of wound tissues. Collagen content rate was assessed to demonstrate the level of minimization and game plan of collagen filaments. Epidermal thickness of those injuries treated with salve of ZnO nanoparticles was fundamentally higher than those of the other two medicines. It was discovered that injuries which were treated with ZnO nanoparticle balm built up an epidermal thickness of 129.04 mm. This outcome is far superior when contrasted with injuries treated with citrus extract salve and ordinary saline. Subsequently, ZnO nanoparticles treatment demonstrated factually noteworthy ($p < 0.05$).

Table I. The histopathological morphometric parameters such as thickness of epidermis and dermis and collagen content of wound.

Treatment	Thickness of epidermis (mm)	Thickness of dermis (mm)	Collagen content (mm)
Normal saline	13.89	870.11	77.02
Zinc oxide nanoparticle	129.04	1821.05	91.98
Citric acid	34.99	1602.3	84.06

It was further observed that treatment of ZnO nanoparticles created better dermis thickness than balm of citrus extract and ordinary saline. Salve of ZnO nanoparticles created obviously better outcomes than the other two medications. It was discovered that typical saline grew slightest thickness of dermis when contrasted with salve of zinc oxide nanoparticles and citrus extract.

Those injuries treated with ZnO nanoparticle balm were found with unrivaled collagen substance. Collagen strands were found in a minimal shape in those injuries treated with balm of ZnO nanoparticles, compared with injuries treated with citrus extract and ordinary saline. So, treatment of ZnO nanoparticles was found to be measurably noteworthy ($p < 0.05$). Citrus extract makes collagen material, which reduces the amount of vascularization. Using normal saline, we found a small amount of vascularization and uneven collagen filament spacing. Wounds which were treated with ordinary saline were not completely recuperated. The correlation of methods for all outcomes uncovered as shown in Table I, in which collagen content rate was significantly higher in wounds treated with nanoparticles of ZnO when contrasted with the other two medications.

DISCUSSION

In order to heal faster, reduce wound bed necrosis, and reduce secondary trauma to the regenerated tissue,

wound dressings should keep the wound moist, protect it from secondary infections, heal the wound faster, and prevent secondary trauma to the regenerated tissue when removed from the healed wound. Furthermore, the wound dressing should be biocompatible with both tissues and blood, non-antigenic, non-toxic, and have adequate elasticity (Ahmed *et al.*, 2019). Nanotechnology now plays an important role in wound healing. Because of their anti-inflammatory and antibacterial properties, zinc oxide nanoparticles can aid in wound healing. It can significantly treat the major condition of the integumentary system live dermatitis skin wounds and blisters (Haritha *et al.*, 2012). Healing a wound is a complex and dynamic process that restores cellular structures and tissue layers as closely as possible to normal. The process of wound contracture occurs throughout the healing process, beginning in the fibroblastic stage with the shrinkage of the wound area. At the maturational stage of wound healing, scar tissue appears to be reduced in size after contraction of the wound (Midwood *et al.*, 2004).

In the current study, the wound healing efficiency of ZnO nanoparticles was found statistically significant, compared with those of citric acid ointment and normal saline. In our study, wound contraction results corroborate with the ZnO-NPs-HCs effect on wound healing described by Le *et al.* (2022). In our study the thickness of epidermis was significantly higher than the two other used drugs. ZnO was applied locally to partial thickness skin wounds in domestic pigs and was applied to the wounds to see if it promoted the healing of the wounds (Agren *et al.*, 1991). In current study the treatment of ZnO nanoparticles created better dermis thickness. Lansdown *et al.* (2007) reported that topical ZnO improves wound healing by 30% in partial thickness and full thickness wounds. Topical Zinc administration appears to reduce super infections and necrotic material more effectively than oral zinc therapy due to its enhancement of local defense systems and collagen-olytic activity. Additionally, it stimulates the epithelialization of wounds in normozincemic individuals by releasing zinc ions that sustain their release (Lansdown *et al.*, 2007). Another study shows that topical application of ZnO accelerates wound healing by anti-bacterial, anti-inflammatory effects, acceleration of reepithelization and metalloenzymes activation by ill-defined mechanism (Lansdown *et al.*, 2007; Aksoy *et al.*, 2010).

In our study injuries treated with ZnO nanoparticle balm were found with unrivaled collagen substance. Collagen strands were found in a minimal shape in those injuries treated with balm of ZnO nanoparticles when contrasted with those injuries treated with citrus extract and ordinary saline. So, treatment of ZnO nanoparticles was found measurably noteworthy ($p < 0.05$). Among

others, collagen synthesis in normal wound healing is expected to be maximal on the 21st day, and then to decline thereafter (Wolfram *et al.*, 2009). In addition, we examined bacterial and fungal growth, and no significant growth was found in these categories (Asad *et al.*, 2018). The ZnO nanoparticles have shown very promising results because of having very characteristic features to inhibit the entrance of bacteria in the wound especially *Staphylococcus aureus* and *E. coli* and to prevent the wound infection. Moreover, the impact on wound healing rises (Rao *et al.*, 2003). Many wounds, particularly those caused by bacteria resistant to numerous antibiotics, have been found to respond quite well to the treatment with citric acid (Nagoba *et al.*, 2010). Additionally, it has been claimed that citric acid not only prevents infection but also encourages the growth of healthy granulation tissue (Nagoba *et al.*, 2008).

CONCLUSION

After evaluating the results of our study, it can be concluded that ZnO nanoparticle ointment has better wound healing efficiency than commercially available ointment and normal saline. In wounds treated with ZnO nanoparticles, wound healing times were drastically reduced. In addition, a large capillary bed was observed at wound site, as well as an increase in collagen fiber percentage. ZnO nanoparticle ointment's enhanced healing properties can be explained by all these aspects.

ACKNOWLEDGEMENTS

Authors would like to thank Dr. Hussain Ali, Veterinary Officer Livestock and Dairy Development Department (extension) Khyber Pakhtunkhwa for the support to conduct the study.

Funding

The study received no external funding.

Ethical statement

Experimental observations on animal care and handling were conducted in accordance with the guide for the use and care of Laboratory Animals of the University of Agriculture Faisalabad, and were approved by University of Agriculture Faisalabad, Laboratory of Animal Management and Bioethics Committee (2010-ag-2502).

Statement of conflict of interest

The authors have declared no conflict of interest.

REFERENCES

- Agren, M.S., Chvapil, M. and Franzén, L., 1991. Enhancement of re-epithelialization with topical zinc oxide in porcine partial-thickness wounds. *J. Surg. Res.*, **50**: 101-105. [https://doi.org/10.1016/0022-4804\(91\)90230-J](https://doi.org/10.1016/0022-4804(91)90230-J)
- Ahmed, A.S., Taher, M., Mandal, U.K., Jaffri, J.M., Susanti, D., Mahmood, S. and Zakaria, Z.A., 2019. Pharmacological properties of *Centella asiatica* hydrogel in accelerating wound healing in rabbits. *BMC Complement. Altern. Med.*, **19**: 1-7. <https://doi.org/10.1186/s12906-019-2625-2>
- Aksoy, B., Atakan, N., Aksoy, H.M., Tezel, G.G., Renda, N., Ozkara, H.A. and Onder, E., 2010. Effectiveness of topical zinc oxide application on hypertrophic scar development in rabbits. *Burns*, **36**: 1027-1035. <https://doi.org/10.1016/j.burns.2010.01.020>
- Asad, K., Sadaf, A., Hamid, A., Imran, A., Usman, G., Mirza, M.U., Imad, K., Sajid, K.T., Raheela, A. and Iftikhar, A.K., 2018. Comparative study of traditional formaldehyde versus formaldehyde free- saturated salt as embalmig solutions for gross anatomy and surgical training of students. *Indo Am. J. Pharma. Sci.*, **5**: 9956-9963.
- Chhabra, S., Chhabra, N., Kaur, A. and Gupta, N., 2017. Wound healing concepts in clinical practice of OMFS. *J. Maxillofac. Oral. Surg.*, **16**: 403-423. <https://doi.org/10.1007/s12663-016-0880-z>
- Ghasemi, F. and Jalal, R., 2016. Antimicrobial action of zinc oxide nanoparticles in combination with ciprofloxacin and ceftazidime against multidrug-resistant *Acinetobacter baumannii*. *J. Glob. Antimicrob. Resist.*, **6**: 118-122. <https://doi.org/10.1016/j.jgar.2016.04.007>
- Gupta, M., Mahajan, V.K., Mehta, K.S. and Chauhan, P.S., 2014. Zinc therapy in dermatology: A review. *Dermatol. Res. Pract.*, pp. 709152. <https://doi.org/10.1155/2014/709152>
- Haritha, Y.K., Ravi, K.J., Basha, S.I., Deshmukh, G., Gujjula, R. and Santhamma, B., 2012. Wound healing activity of topical application of Aloe vera gel in experimental animal models. *Int. J. Pharma Bio Sci.*, **3**: P63-P72.
- Holmes, A.M., Song, Z., Moghimi, H.R. and Roberts, M.S., 2016. Relative penetration of zinc oxide and zinc ions into human skin after application of different zinc oxide formulations. *ACS Nano*, **10**: 1810-1819. <https://doi.org/10.1021/acsnano.5b04148>
- Lansdown, A.B., Mirastschijski, U., Stubbs, N., Scanlon, E. and Agren, M.S., 2007. Zinc in wound healing: Theoretical, experimental, and clinical aspects. *Wound Repair. Regen.*, **15**: 2-16. <https://doi.org/10.1111/j.1524-475X.2006.00179.x>
- Le, V.A.T., Trinh, T.X., Chien, P.N., Giang, N.N., Zhang, X.R., Nam, S.Y. and Heo, C.Y., 2022. Evaluation of the performance of a ZnO-nanoparticle-coated hydrocolloid patch in wound healing. *Polymers (Basel)*, **14**: 919. <https://doi.org/10.3390/polym14050919>
- Malu, R.G., Nagoba, B.S., Jaju, C.R., Suryawanshi, N.M., Mali, S.A., Goyal, V.S. and Misal, N.S., 2016. Topical use of citric acid for wound bed preparation. *Int. Wound J.*, **13**: 709-712. <https://doi.org/10.1111/iwj.12351>
- Midwood, K.S., Williams, L.V. and Schwarzbauer, J.E., 2004. Tissue repair and the dynamics of the extracellular matrix. *Int. J. Biochem. Cell Biol.*, **36**: 1031-1037. <https://doi.org/10.1016/j.biocel.2003.12.003>
- Nagoba, B.S., Gandhi, R.C., Wadher, B.J., Gandhi, S.P. and Selkar, S.P., 2010. Citric acid treatment of necrotizing fasciitis: A report of two cases. *Int. Wound J.*, **7**: 536. <https://doi.org/10.1111/j.1742-481X.2010.00721.x>
- Nagoba, B.S., Gandhi, R.C., Wadher, B.J., Potekar, R.M. and Kolhe, S.M. 2008. Microbiological, histopathological and clinical changes in chronic infected wounds after citric acid treatment. *J. med. Microbiol.*, **57**: 681-682. <https://doi.org/10.1099/jmm.0.47647-0>
- Natarajan, S., Williamson, D., Stiltz, A.J. and Harding, K., 2000. Advances in wound care and healing technology. *Am. J. Clin. Dermatol.*, **1**: 269-275. <https://doi.org/10.2165/00128071-200001050-00002>
- Negut, I., Grumezescu, V. and Grumezescu, A.M., 2018. Treatment strategies for infected wounds. *Molecules*, **23**: 2392. <https://doi.org/10.3390/molecules23092392>
- Norman, G., Dumville, J.C., Mohapatra, D.P., Owens, G.L. and Crosbie, E.J., 2016. Antibiotics and antiseptics for surgical wounds healing by secondary intention. *Cochrane Datab. Syst. Rev.*, **3**: Cd011712. <https://doi.org/10.1002/14651858.CD011712>
- Rao, G.V.S., Selvaraj, J., Ramanan, R.S., Radhakrishnan, N. and Manohar, B.M., 2003. Efficacy of some indigenous medicines in wound healing in rats. *Indian J. Anim. Sci. (India)*, **73**: 652-653.
- Sandhya, R.D., Samskruti, G. and Sudhakar D., 2021. Different types of wounds management in buffaloes. *Pharma Innov. J.*, **11**: 200-204.

- Sheferov, I., Balakireva, A., Pantelev, D., Spitskaya, I., Orekhov, S., Kazantsev, O. and Melnikova, N., 2022. The effect of zinc oxide nanoparticles on properties and burn wound healing activity of thixotropic xymedone gels. *Sci. Pharma.*, **90**: 61. <https://doi.org/10.3390/scipharm90040061>
- Souza, R.C.D., Haberbeck, L.U., Riella, H.G., Ribeiro, D.H. and Carciofi, B.A., 2019. Antibacterial activity of zinc oxide nanoparticles synthesized by solochemical process. *Braz. J. chem. Eng.*, **36**: 885-893. <https://doi.org/10.1590/0104-6632.20190362s20180027>
- Stojadinovic, A., Carlson, J.W., Schultz, G.S., Davis, T.A. and Elster, E.A., 2008. Topical advances in wound care. *Gynecol. Oncol.*, **111**: S70-80. <https://doi.org/10.1016/j.ygyno.2008.07.042>
- Wolfram, D., Tzankov, A., Pülzl, P. and Piza-Katzer, H., 2009. Hypertrophic scars and keloids. A review of their pathophysiology, risk factors, and therapeutic management. *Dermatol. Surg.*, **35**: 171-181. <https://doi.org/10.1111/j.1524-4725.2008.34406.x>
- Xie, Y., He, Y., Irwin, P.L., Jin, T. and Shi, X., 2011. Antibacterial activity and mechanism of action of zinc oxide nanoparticles against *Campylobacter jejuni*. *Appl. Environ. Microbiol.*, **77**: 2325-2331. <https://doi.org/10.1128/AEM.02149-10>

Online First Article